



**Overseas Specialist Surgical Association of Australia
(OSSAA)**

**Hospital Regional Eduardo Ximenes (HoREX)
Baucau, Timor Leste**

Plastic and Reconstructive Surgery team visit

30 Nov – 5 Dec 2025

Plastic and Reconstructive Surgery team visit

30 Nov – 5 Dec 2025

Dr Mark Moore, AM, FRACS

Plastic and Craniofacial Surgeon

Team Leader, OSSAA

INTRODUCTION:

The OSSAA reconstructive surgical team visit to HoREX, Baucau occurred in response to the very high number of patients with cleft lip and palate who were assessed on our team's August visit to Dili, but were unable to have surgery at that time. Whilst more than 40 cleft operations were performed in August, there were more than 80 patients waitlisted. Having identified this week in early December as a suitable time to assemble a team, the presence of a visiting Australian Paediatric Surgical team at HNGV in Dili meant we contacted and sought approval from the HoREX administration to locate our team in their hospital. This also allowed us to target those patients from the eastern regions of Timor Leste. From the August waitlist we identified about 30 patients from the Baucau/ Los Palos region, as well as a few from Dili who had been deferred on multiple occasions and tasked Dr Mingota (who is acting as our local counterpart as part of her involvement with PAS clinic) with contacting these patients. By limiting the numbers we hoped to avoid disappointing too many patients once again.

In addition to the absence of Dr Joao Ximenes, now away in Cuba for training, we have had to face the prospect of working there without the support and organisational skills of Mr Mok, who is now in Japan studying for a postgraduate degree. Despite this he was very helpful in coordinating the visit via WhatsApp and other messaging platforms.

TEAM PERSONNEL :

The visiting OSSAA team on this visit to HoREX was as follows:

Dr Mark Moore	Plastic and Craniofacial Surgeon Women's and Children's Hospital and Royal Adelaide Hospital, Adelaide
Dr Pragaash Shanmuganathan	Plastic and Reconstructive Surgeon Women's and Children's Hospital and Royal Adelaide, Adelaide
Dr Matthew Grill	Anaesthetist Women's and Children's Hospital and Private Practice, Adelaide
Sr Josephine Luke	Theatre Nurse Women's and Children's Hospital, Adelaide
Sr Amanda McFall	Anaesthetic/ Recovery Nurse Women's and Children's Hospital, Adelaide

PARTICIPATING LOCAL STAFF AND COUNTERPARTS :

The organisation for the visit was shared between Mr Mok, our local nurse colleague, albeit now studying in Japan and Dr Mingota, a consultant anaesthetist who has worked with our team in Dili previously and who now does some volunteer work with Maria Dias at PAS clinic in Becora, Dili. Between them, they were able to obtain customs clearance documents for entry into Timor Leste, as well as liaising with the administration of HoREX and contacting the waitlist of patients.

The outpatient clinic held in the Emergency Department on Sunday was overseen by Dr Mauzinho F da Costa Belo (Clinical Director).

Within the operating theatre complex we were working alongside many old friends and nursing colleagues, some who have dealings with our teams for 10-20 years or more. These included Regina, Valerio, Anselmo, Batista, and Cico, as well as those who are more junior and

have had less time with our teams. Recovery was staffed by our team in association with a range of junior nurses.

Josie, our scrub nurse worked with the local sterilising staff in ensuring instrument availability and turnover.

OVERVIEW:

The OSSAA team visit to HoREX was instituted to attempt to deal with the backlog of cleft lip and palate cases in Timor Leste – this only increasing with Dr JX being away in Cuba, and no suitable fill-in having yet been identified.

Travel through to Baucau from Adelaide was possible in the one day – the Hotel Realistic in Baucau providing two cars to transport our team and luggage from Dili, and return us there the week later. Arriving late in the day we could rest before the planned clinic at the hospital on Sunday morning.

From the large list of patients screened in Dili in August we extracted a subset of cases whose homes are in the eastern districts, or who had been multiply deferred from areas closer to Dili, but willing to travel to Baucau. Dr Ming contacted as many of these from a list of about 30 cases who we had contact phone numbers for. On the Sunday consulting and the following few days fourteen of these cases presented for surgery. One case seen last year in Dili with an external ear deformity also returned and proceeded to surgery. Over the whole week we saw 27 cases with the majority presenting on Sunday.

Full surgical lists were constructed for Monday and Tuesday, in anticipation of more cases presenting. Wednesday was a slightly lighter workload, with Thursday a free day before we returned to do 3 smaller cases on Friday. This allowed all patients to be discharged by Friday afternoon, well before our departure on Saturday morning. As we had little medical officer support for our inpatients during the week it was crucial to have all patients stable and ideally discharged while our team was still present.

Dr Pragaash was a welcome addition to the surgical team – on this his first visit with us, he undertook a number of high quality cleft lip and palate repairs. Dr Matt, our anaesthetist was able to teach local anaesthetic nurses and a number of them had the opportunity to learn

and perform intubation and maintenance of the airway in patients with cleft lip and palate. Our nurses Amanda and Josie were similarly able to teach and instruct their local nursing colleagues in the practices of good quality operating room craft.

Over the week some 19 primary cleft procedures were performed, with on this occasion no revisionary procedures being necessary. By weeks end the team have now completed over 1370 cleft surgical operations since starting in the year 2000. Post operative care of these cases was largely overseen by the surgical ward nurses, with the assistance of the patients families. This made it a little more challenging as we relied on a couple of parents and nurses whose English language skills were better. We also created a glossary of terms translated into Tetum to explain to families aftercare both in hospital and after discharge home.

On the final day, the team was hosted by Dr Claudino Ximenes and Dr Mauzinho representing the HoREX administration who thanked us for our teams work and teaching, and welcomed us to return on at least one occasion in 2026. Having completed our activities we farewelled the operating theatre staff who supported us so professionally and were able to depart by road the following morning for Dili. Thereafter we flew to Darwin after a minor delay due to the airport computer check in system being out of action. An overnight stay in Darwin was followed by the team's flight home to Adelaide early on Sunday morning.

SUMMARY OF CLINICAL ACTIVITIES :

Total Patient Consultations 27

Cleft lip/ palate

Total Surgical Procedures 23

22 patients operated, 1 had two procedures

1° Cleft Lip – unilateral 9
- bilateral 2

1° Cleft palate 8

Scalp trauma/ SSG 2

Prominent ear surgery 1

Keloid surgery 1

Gender :

Male 13

Female 9

Age range :

< 1 year 4

1-2 years 4

2-5 years 6

5-10 years 3

10+ years 5

Primary cleft lip surgery **11**

< 1 year	3
1-2 years	3
2-5 years	4
5-10 years	0
10+ years	1

Primary cleft palate surgery **8**

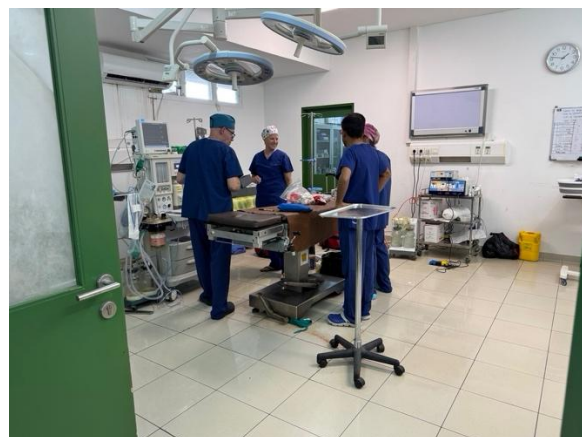
< 1 year	1
1-2 years	1
2-5 years	1
5-10 years	3
10+ years	2

RECOMMENDATIONS:

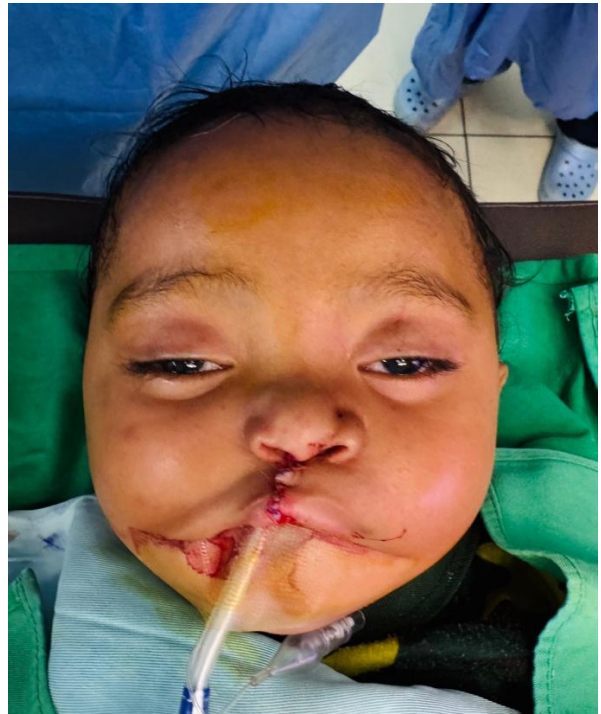
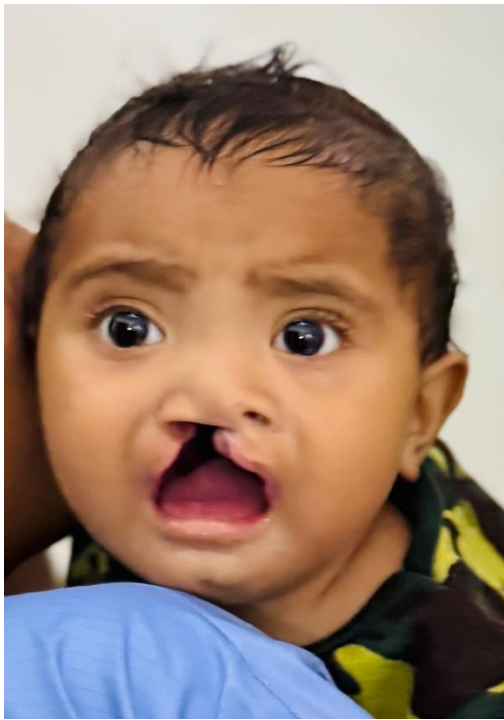1. Continue to maintain the increased frequency of visits to Timor Leste – Dili, Baucau and ? Oecussi.
2. Early determination of visit schedule for 2026 to avoid overlap with other visiting teams (Paediatric Surgery)
3. Work towards a team of local counterparts to assist in continuity of our service, with the assistance of local hospital administrators. Also to seek to identify local medical/ surgical staff who may wish to consider a career in Reconstructive Surgery.



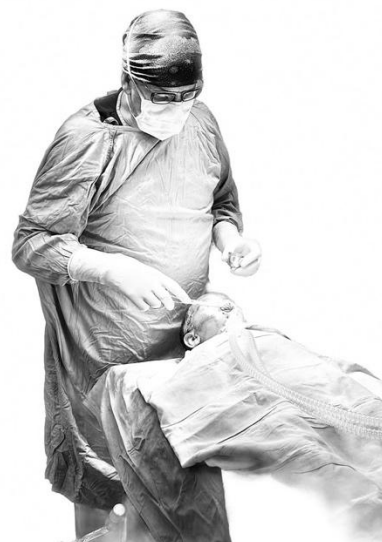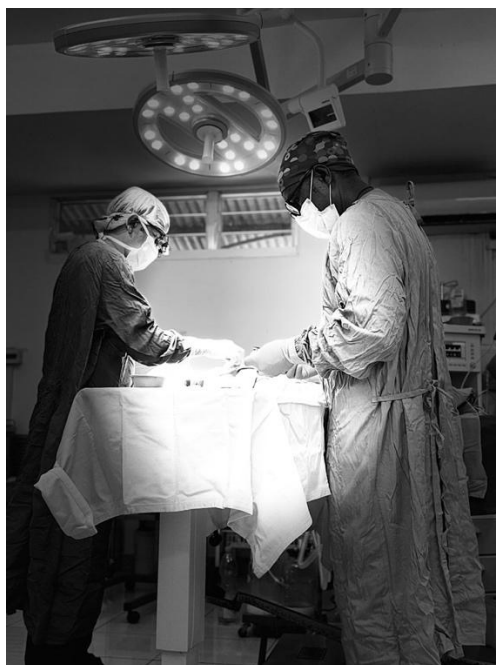Team met by Nora (Mok's wife) and Teo (OT nurse- HNGV) at Dili



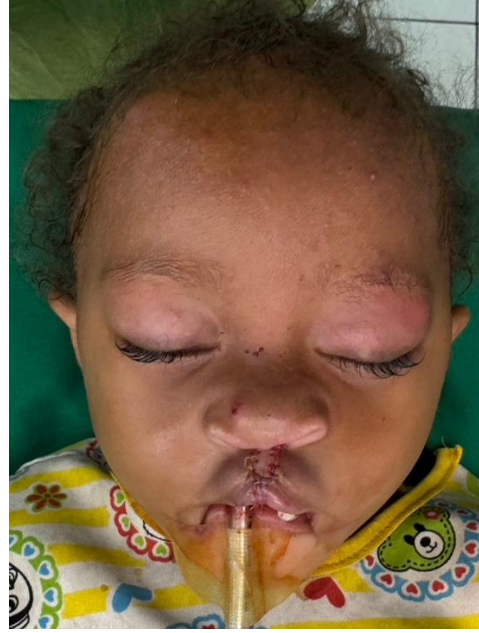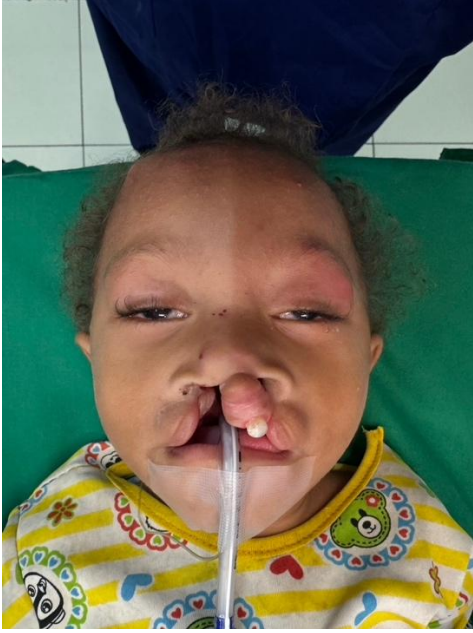HoREX walkways and operating theatre



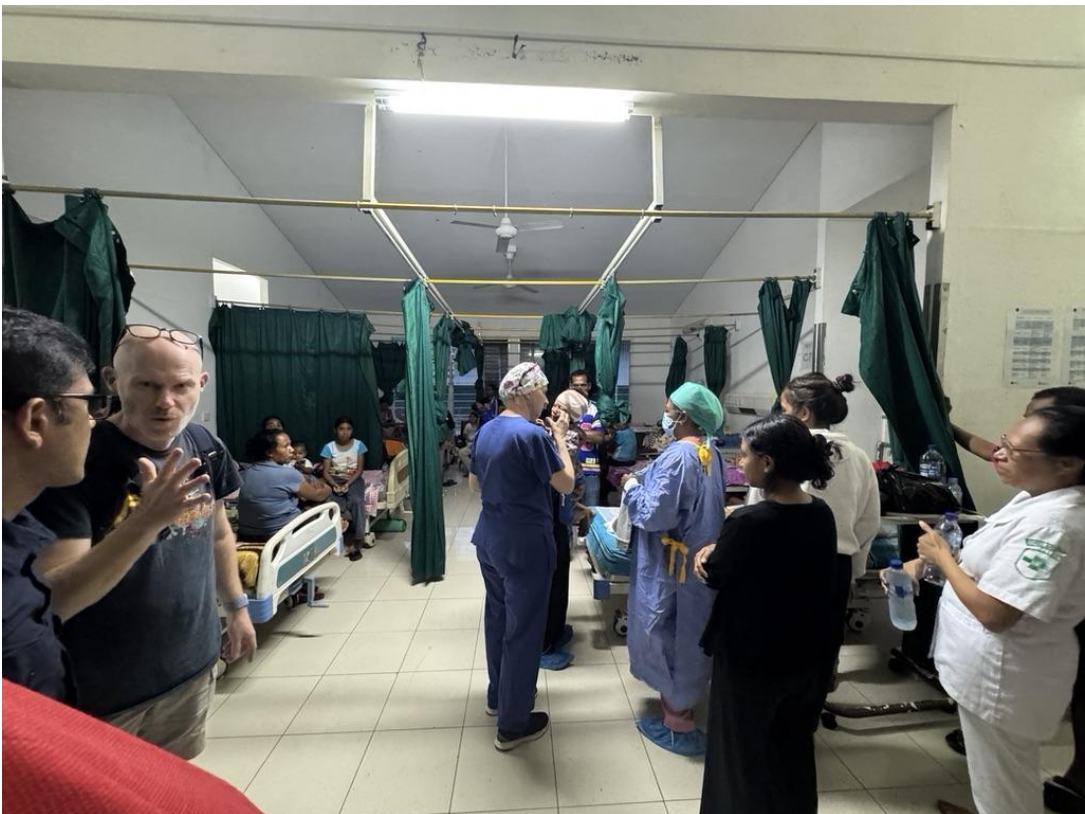Infant with right complete cleft lip and palate – post lip repair



Team surgeons operating



Bilateral cleft lip/ palate – pre- and post-op



Surgical ward – post-op rounds



Team photos with theatre staff and hospital executive